Sparsity-Based Deconvolution for Low-Dose CT Perfusion Enhancement

Ruogu Fang and **Tsuhan Chen**
Department of Electrical and Computer Engineering
Cornell University

Pina C. Sanelli
Department of Radiology, Department of Public Health,
Weill Cornell Medical College

International Symposium on Biomedical Imaging 2013

April 10th, 2013

Motivations of Low-dose CT Perfusion

- **Reduce** radiation dose of CTP at scanning time to as low as reasonably achievable (ALARA)
- **Achieve** high-quality perfusion maps with accurate quantitative values for rapid and correct diagnosis
- **Improve** patient safety and quality of healthcare

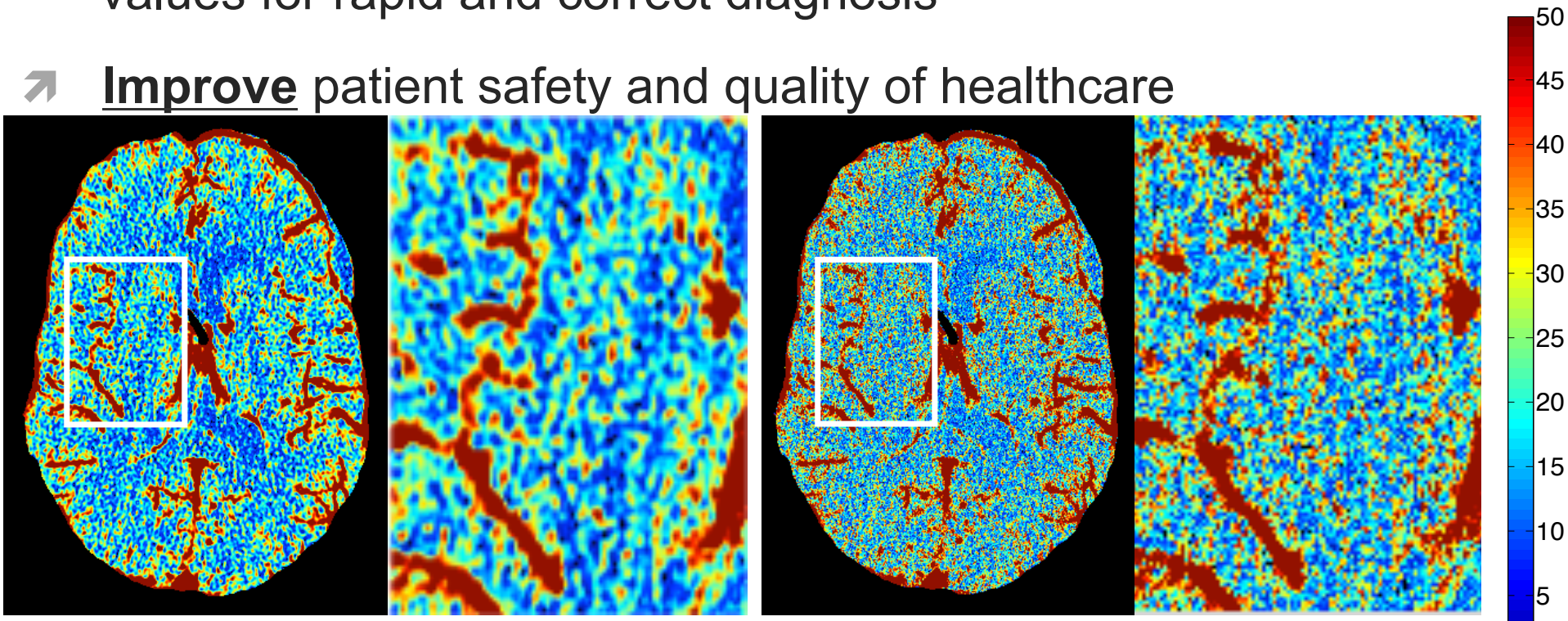

CBF 190mA RMCA CBF 15mA RMCA

Basic Principle of CT Perfusion

INJECT SCAN MODEL DENSITY/INTENSITY CURVES

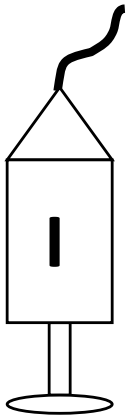

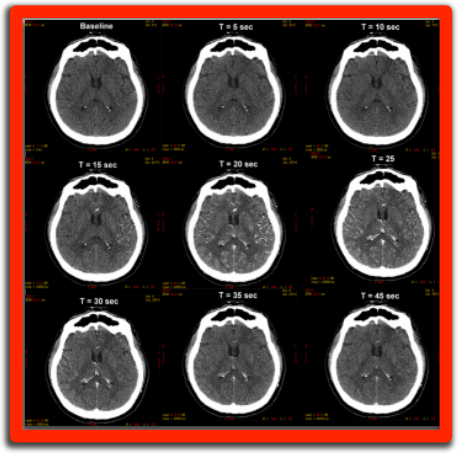

Sanelli PC. Neurographics 2005;4:1-74

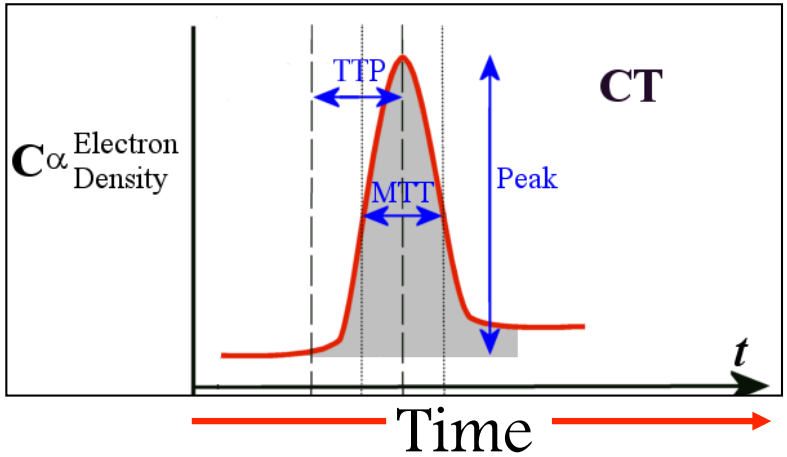

First pass contrast

Dynamic cine scanning

Represents passage of contrast

Deconvolution

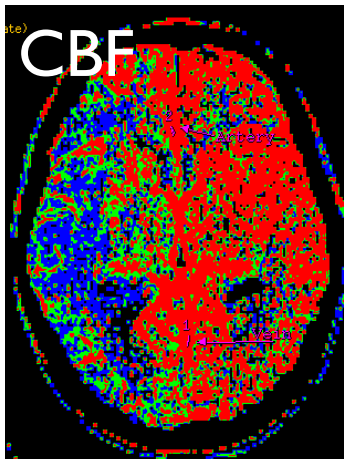

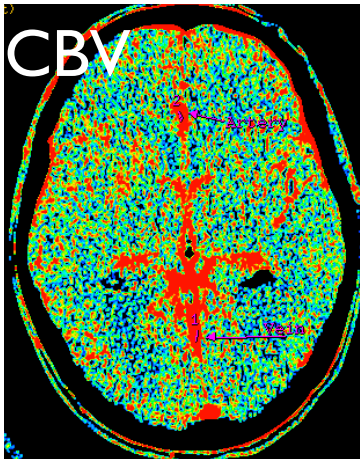

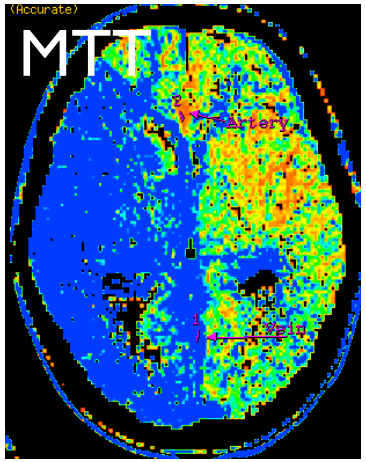

Images credit: Sanelli PC.

Exponential Growth of CT Scanning

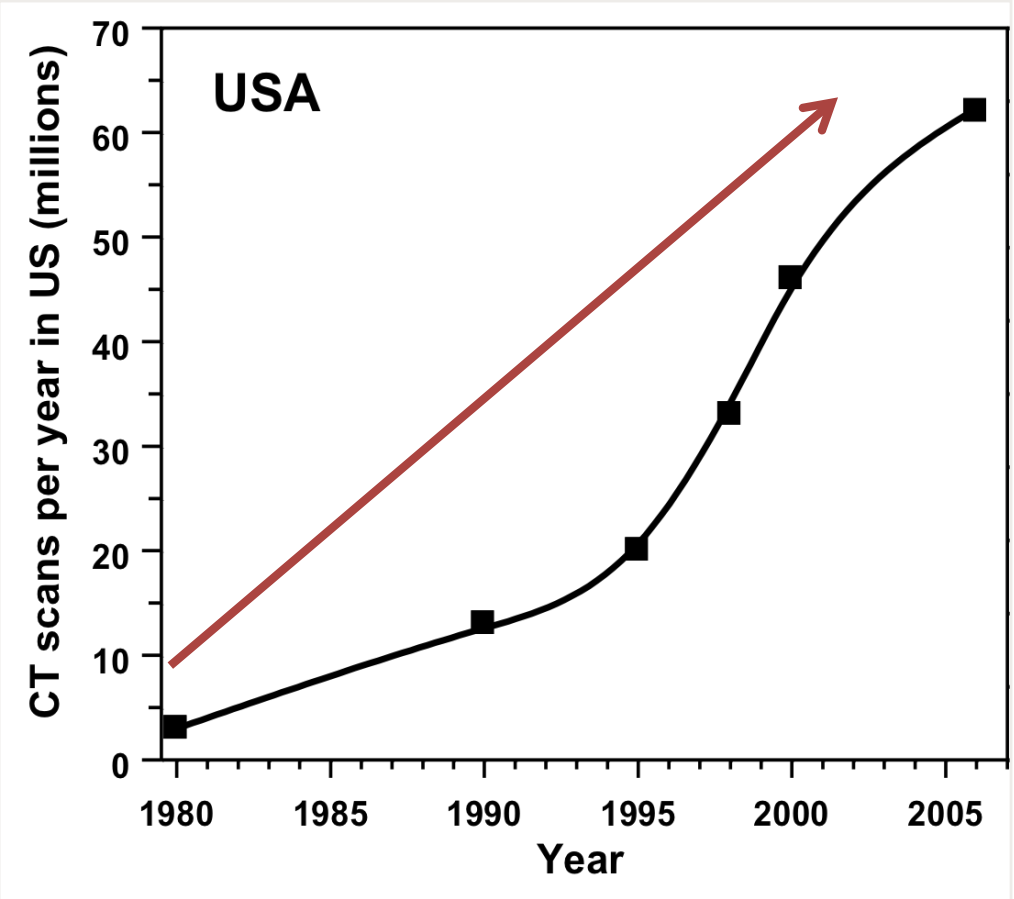

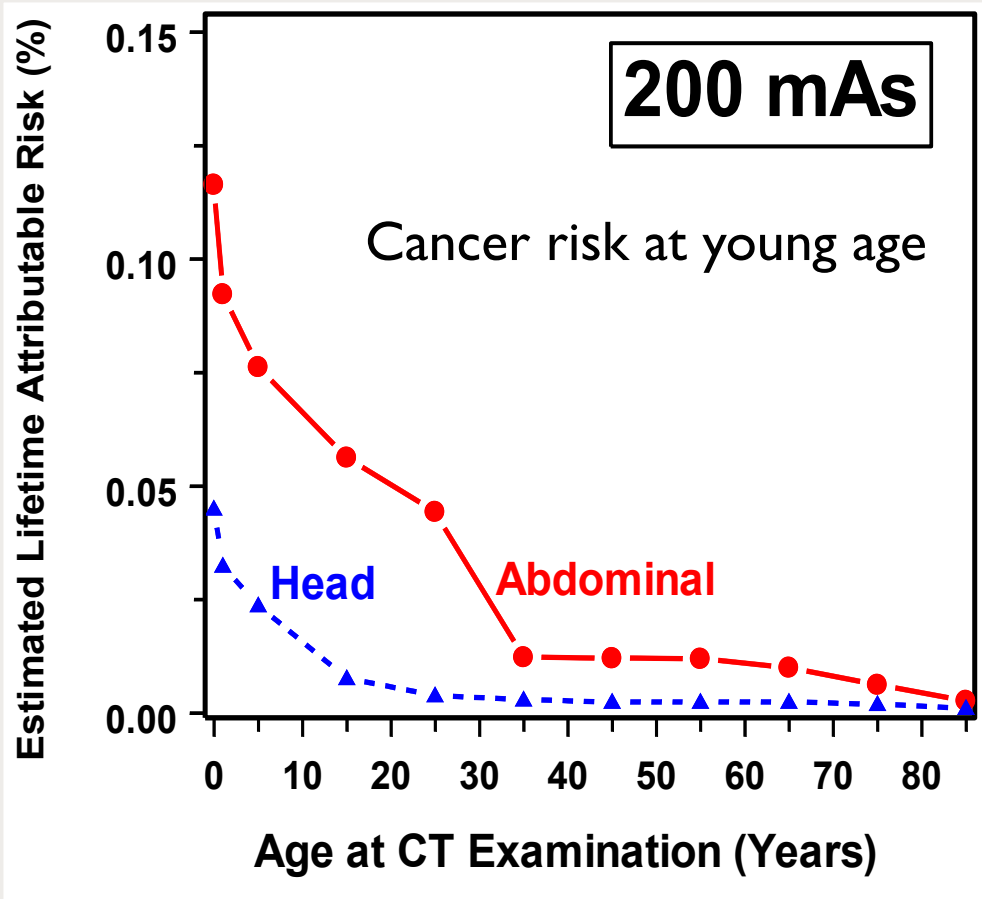

Higher Radiation Dose associated with CT

Examination	Relevant organ	Effective organ dose (mSv)	Estimated dose equivalent (# of chest X-rays)
Dental x ray	Brain	0.005-0.01	0.25-0.50
Chest x ray (PA, lateral)	Lung	0.02	1
Screening mammogram	Breast	0.4	20
CT head	Brain	2.0	100
CT abdominal	Stomach	16.0	800

Compared to most medical imaging, CT produces much higher radiation doses. [Mettler 2008]

Radiation Over-exposure Leads to…

- Radiation Risks to Health: Hair and skin damage, cataract formation, cancer induction, seizure, emotional grief → FDA investigation 2010

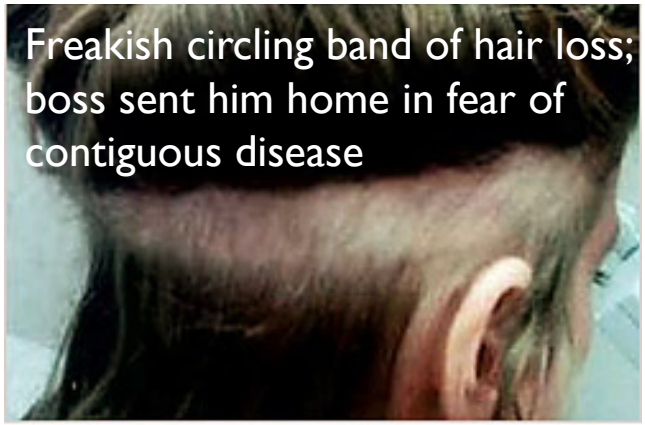

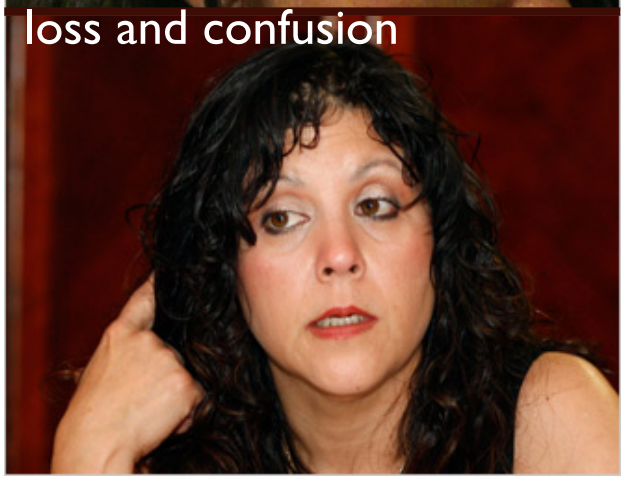

Source: New York Times July 31 2010

Priors in CT Perfusion

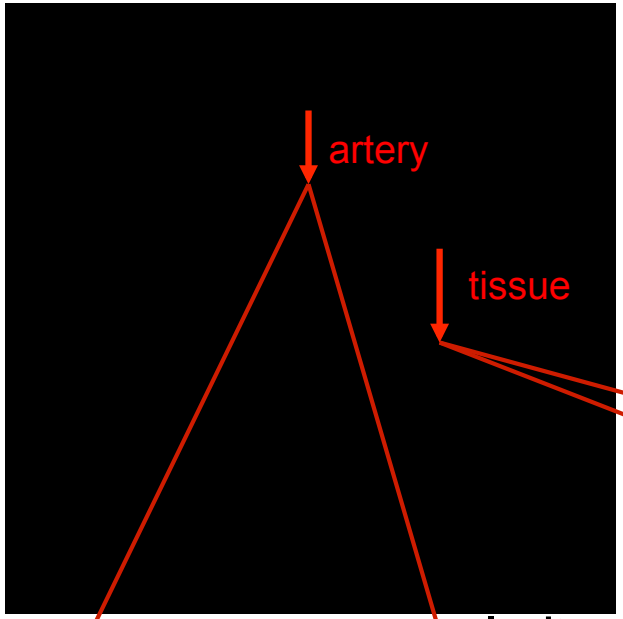

- Regularization priors used to quantify perfusion parameters:
  - Temporal convolution model

Indicator dilution theory

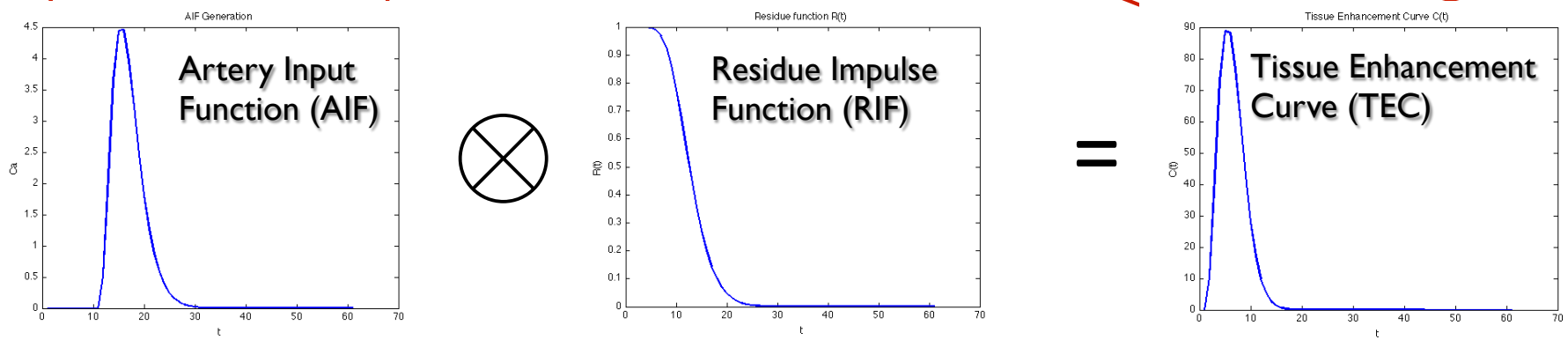

Priors in CT Perfusion

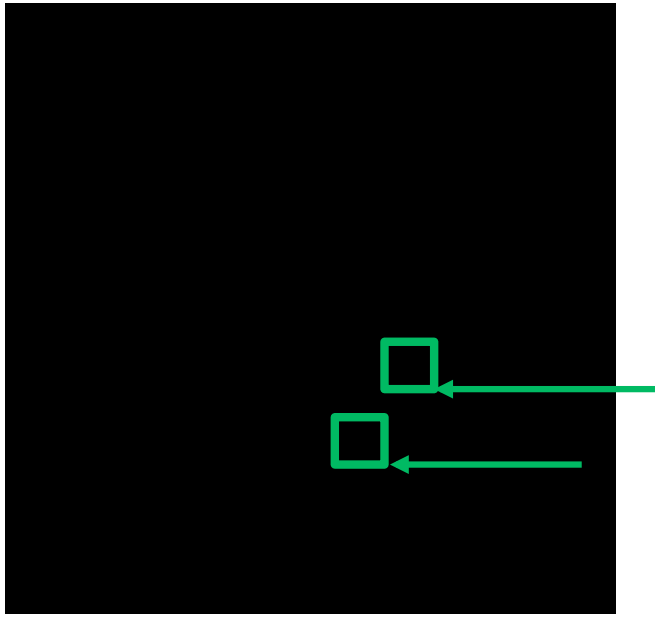

- Regularization priors used to quantify perfusion parameters:
  - Temporal convolution model
  - Spatial coherence

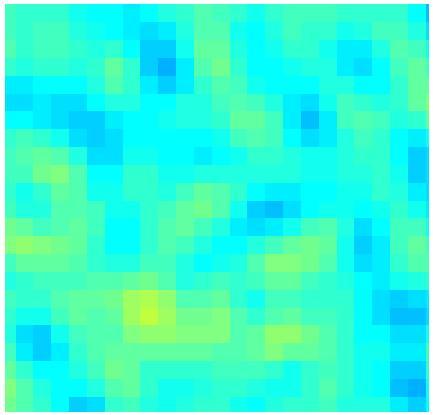

Spatial Smoothness

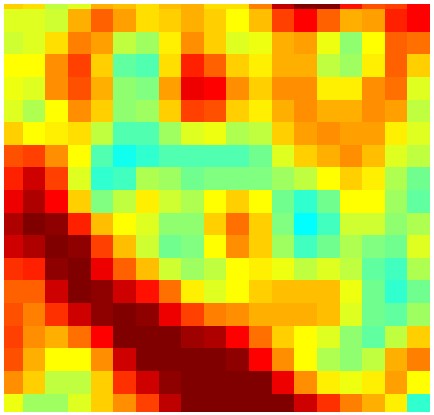

Edge Preserving

Priors in CT Perfusion

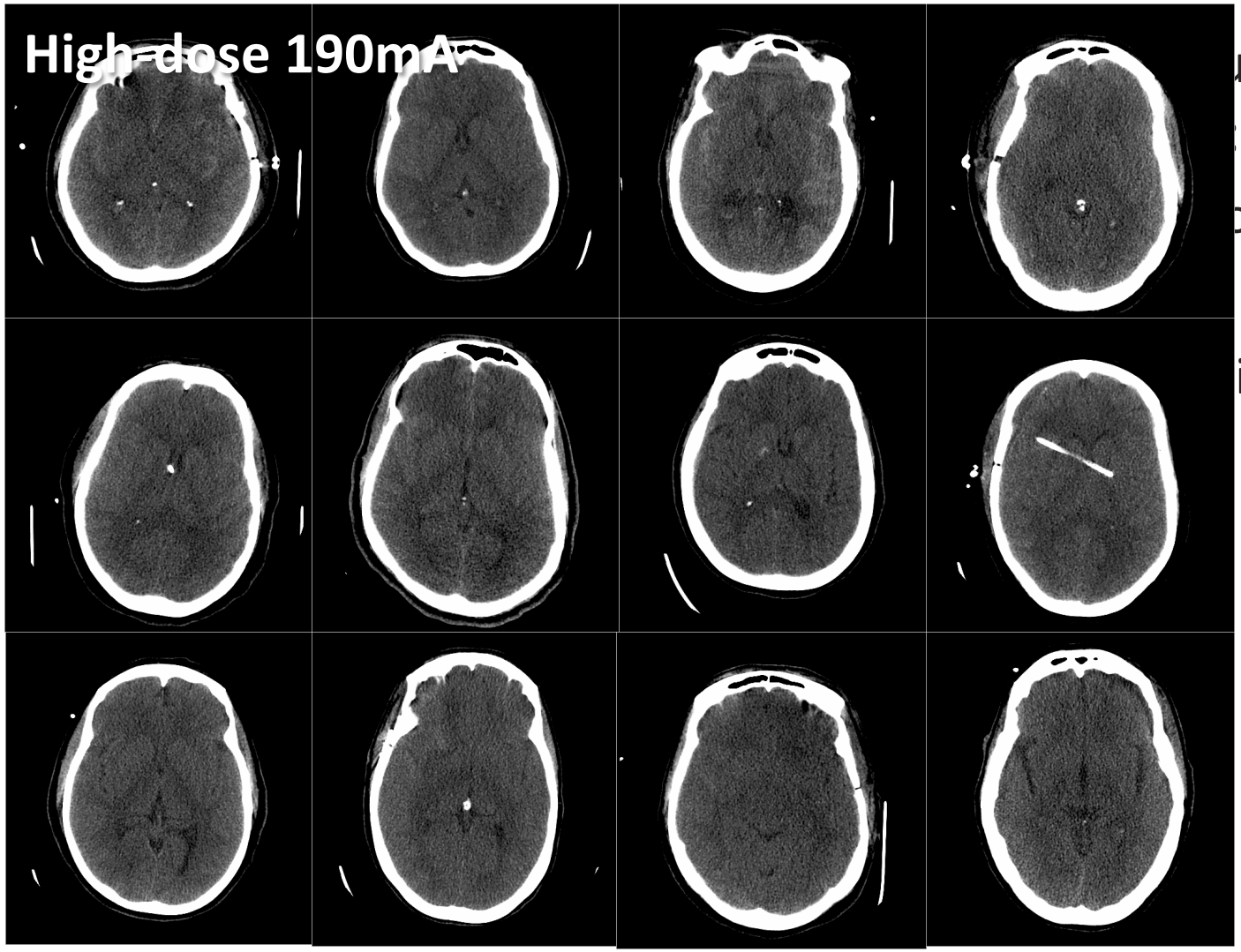

used to quantify

on model

ity

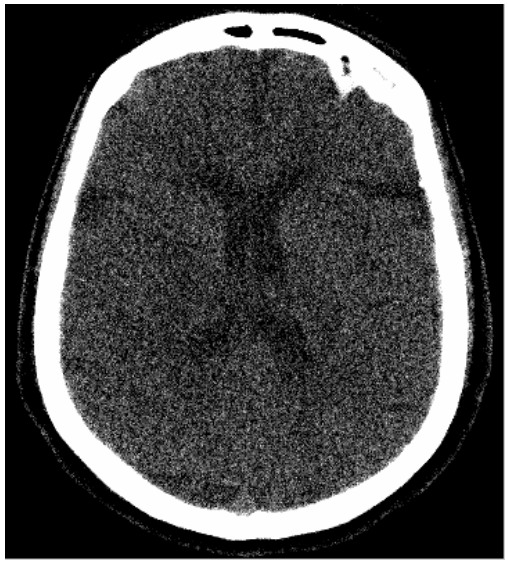

Low-dose 15mA

Related Work

- Sparse and redundant representation

- M. Elad, IEEE Trans. Image Processing, 2006

- Spatial-temporal Regularization

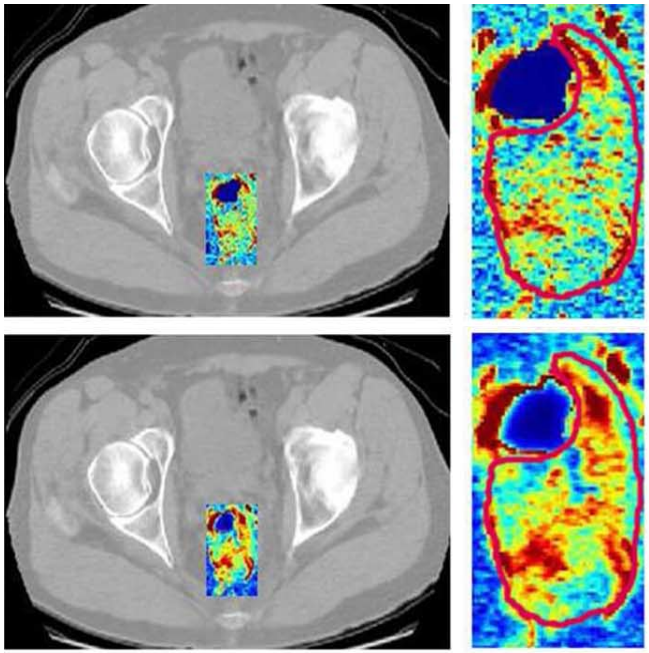

- L. He, IEEE Trans Medical Imaging, 2010

- Example-based Restoration/ Super-resolution



- B. Freeman, Image-based Modeling, Rendering, and Lighting, 2002

- <u>Our contribution:</u> Sparse prior in spatial-temporal restoration by learning from high-dose data

Sparse Prior in Spatial-temporal Restoration

- Construct a dictionary from the high-dose（i.e. low noise) perfusion maps
- Reconstruct the newly-input low-dose (i.e. high noise) perfusion map by sparsely combine the atoms from the dictionary

$$J_{st} = \|\mathbf{C} - \mathbf{C_a}\mathbf{R}\|_2^2 + \mu\|\alpha\|_0$$

Temporal Convolution Model

Sparse Prior

$$s.t. \quad \|\mathbf{D}\alpha - x\|_2^2 \leq \epsilon \qquad x = \mathbf{R}(t=0)$$

Inter-data Similarity

CBF Definition

Sparse Prior in Spatial-temporal Restoration

$$J_{st} = \mu_t \|\mathbf{C} - \mathbf{C_a}\mathbf{R}\|_2^2 + \|\mathbf{D}\alpha - x\|_2^2 + \mu_s \|\alpha\|_1$$

Temporal Convolution Model

Inter-data Similarity

Sparse Prior

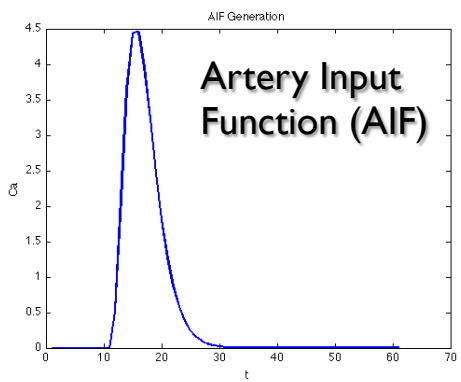

$\otimes$

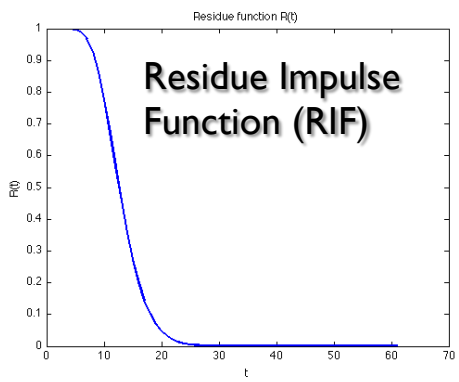

$=$

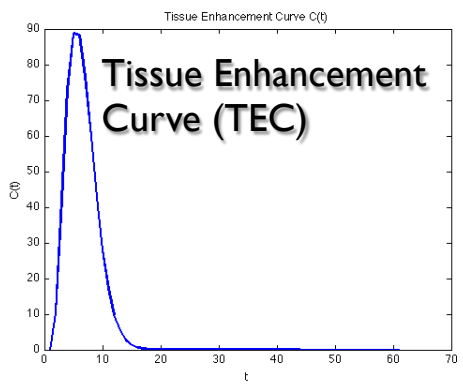

Sparse Prior in Spatial-temporal Restoration

$$J_{st} = \mu_t \|\mathbf{C} - \mathbf{C_a}\mathbf{R}\|_2^2 + \|\mathbf{D}\alpha - x\|_2^2 + \mu_s \|\alpha\|_1$$

Temporal Convolution Model

Inter-data Similarity

Sparse Prior

Online Dictionary Learning

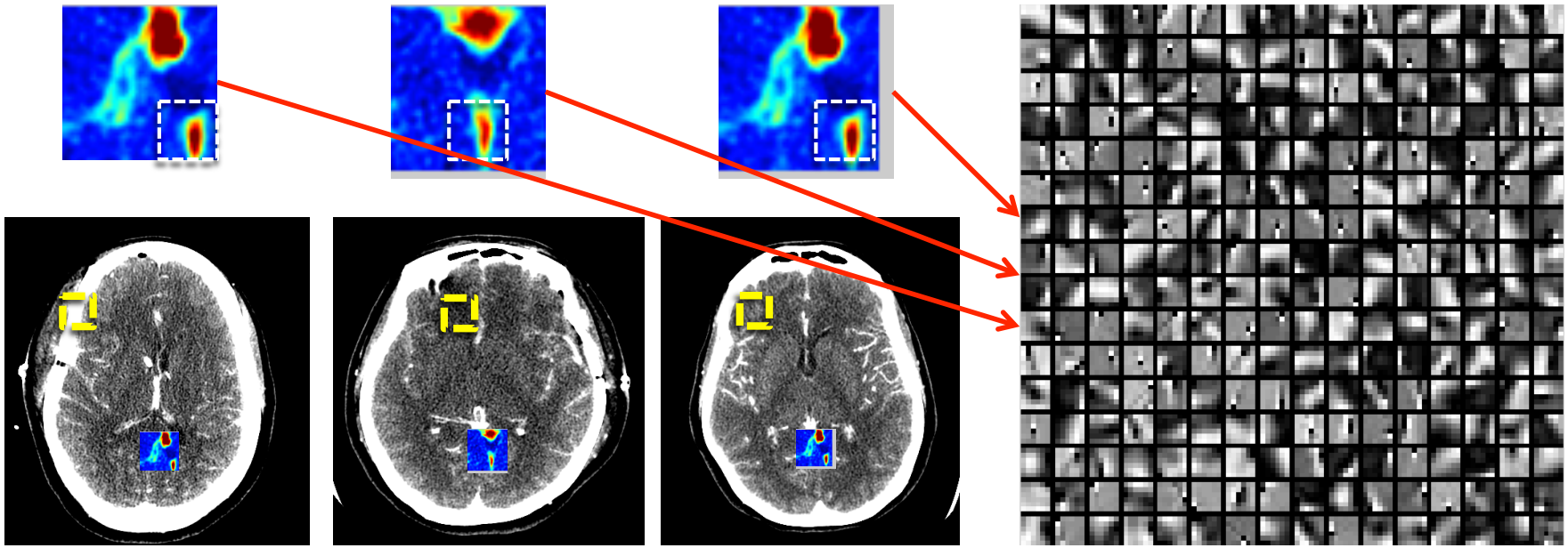

Sparse Prior in Spatial-temporal Restoration

$$J_{st} = \mu_t \|\mathbf{C} - \mathbf{C_a}\mathbf{R}\|_2^2 + \|\mathbf{D}\alpha - x\|_2^2 + \mu_s \|\alpha\|_1$$

Temporal Convolution Model

Inter-data Similarity

Sparse Prior

Quadratic Problem



Lasso

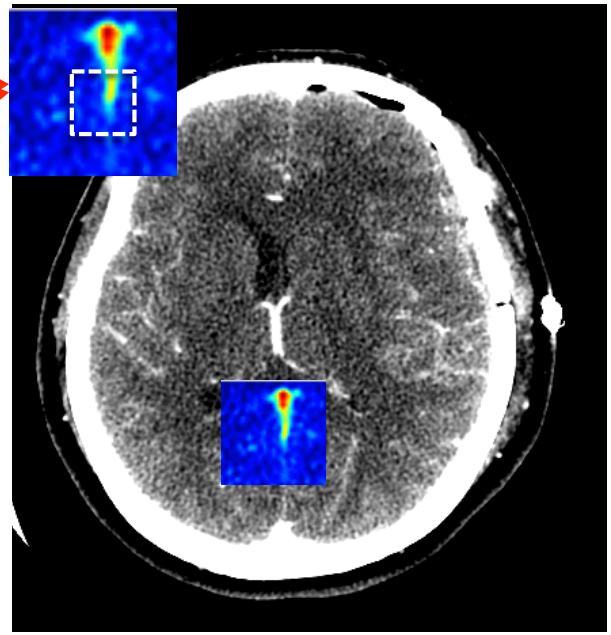

Learned Dictionary from High-Dose

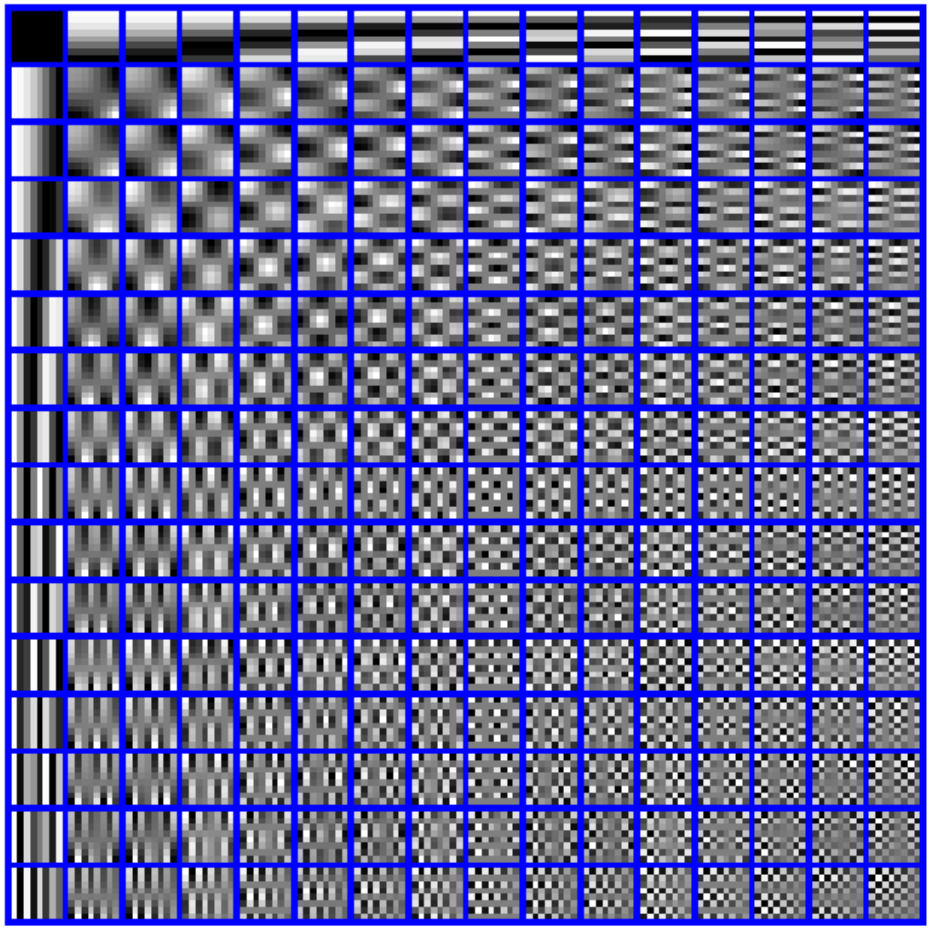

Initial DCT Dictionary



Online Learned Dictionary

DCT vs. Learned Dictionary

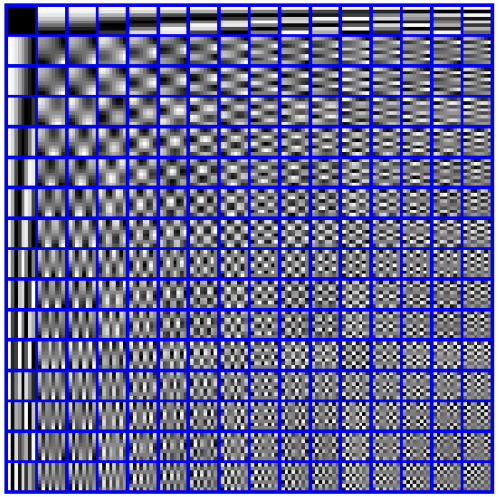

MSE=811.52



MSE=726.57

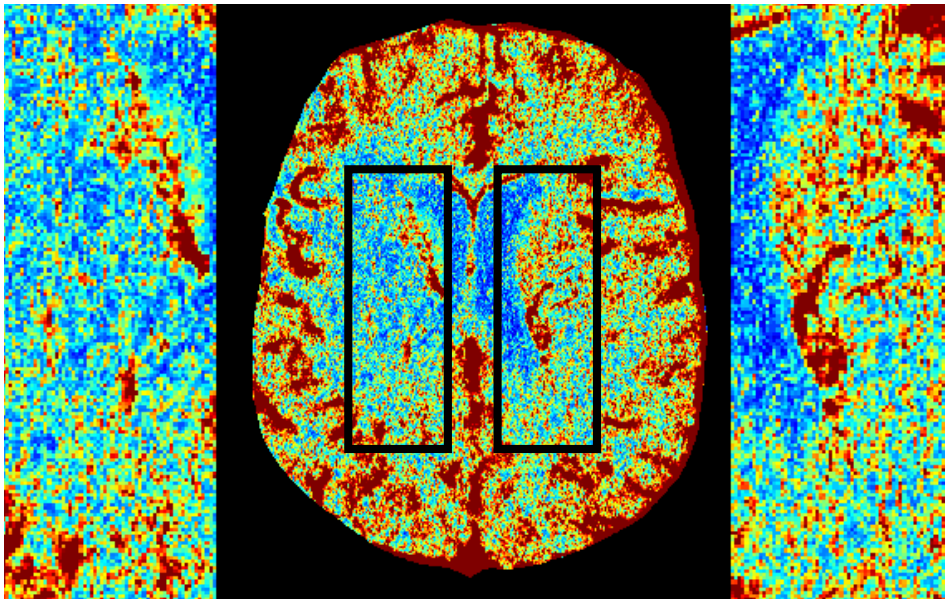

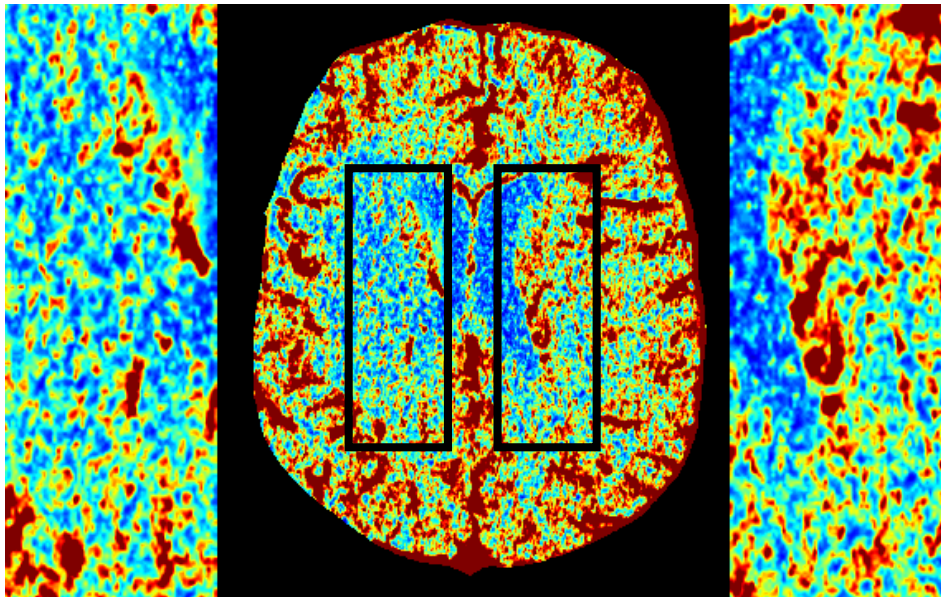

42-yo male with normal cerebral blood flow

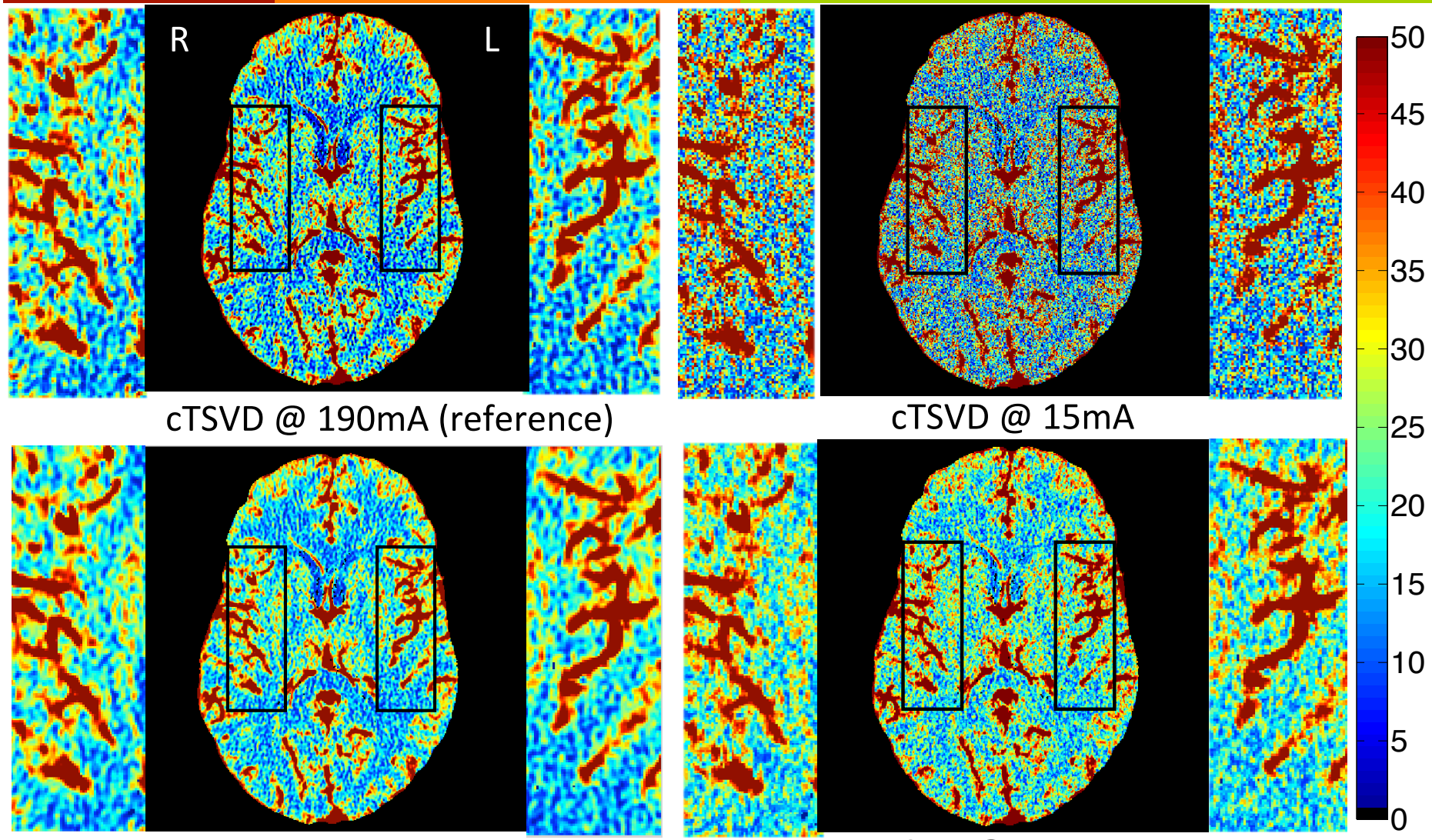

cTSVD @ 190mA (reference)

cTSVD @ 15mA

SPD @ 190mA

SPD @ 15mA

35 yo female with A-SAH (ischemic in left hemisphere)

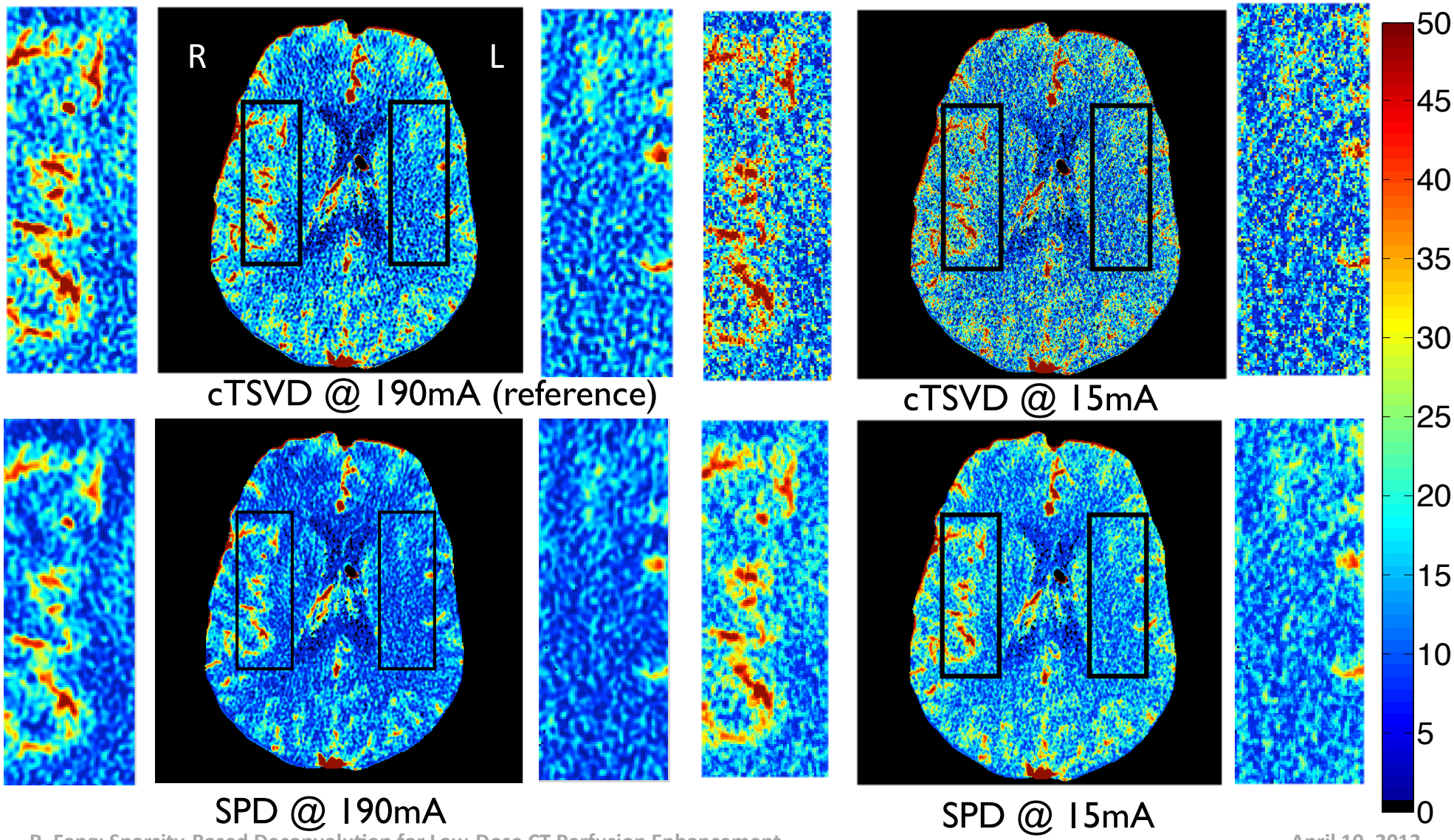

Asymmetry in aneurysmal SAH patient



Ischemic Voxels Detection

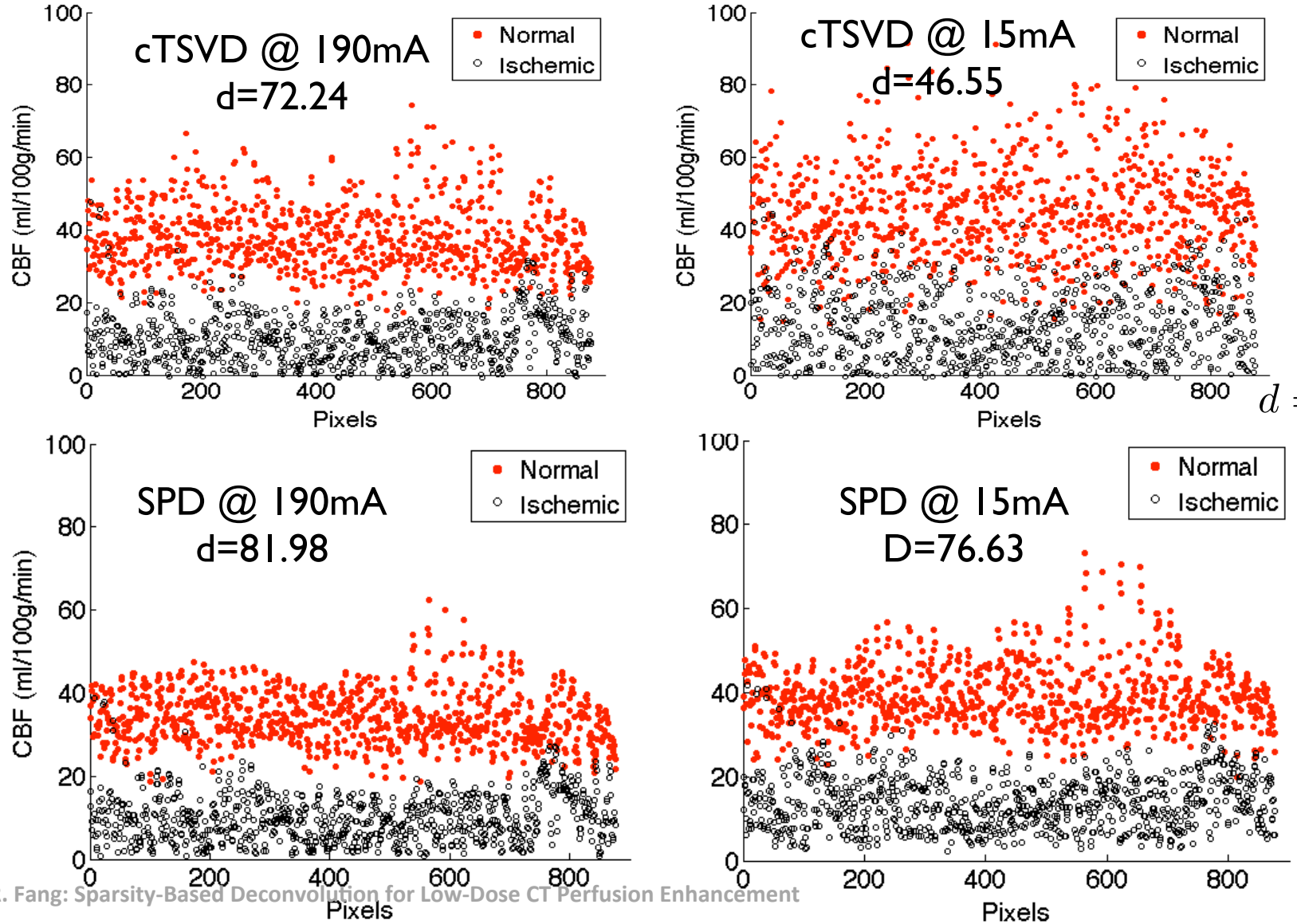

$$d = \frac{m_1 - m_2}{\sqrt{\frac{\sigma_1^2}{n_1} + \frac{\sigma_2^2}{n_2}}}$$

Receiver Operator Curve of Ischemic Detection

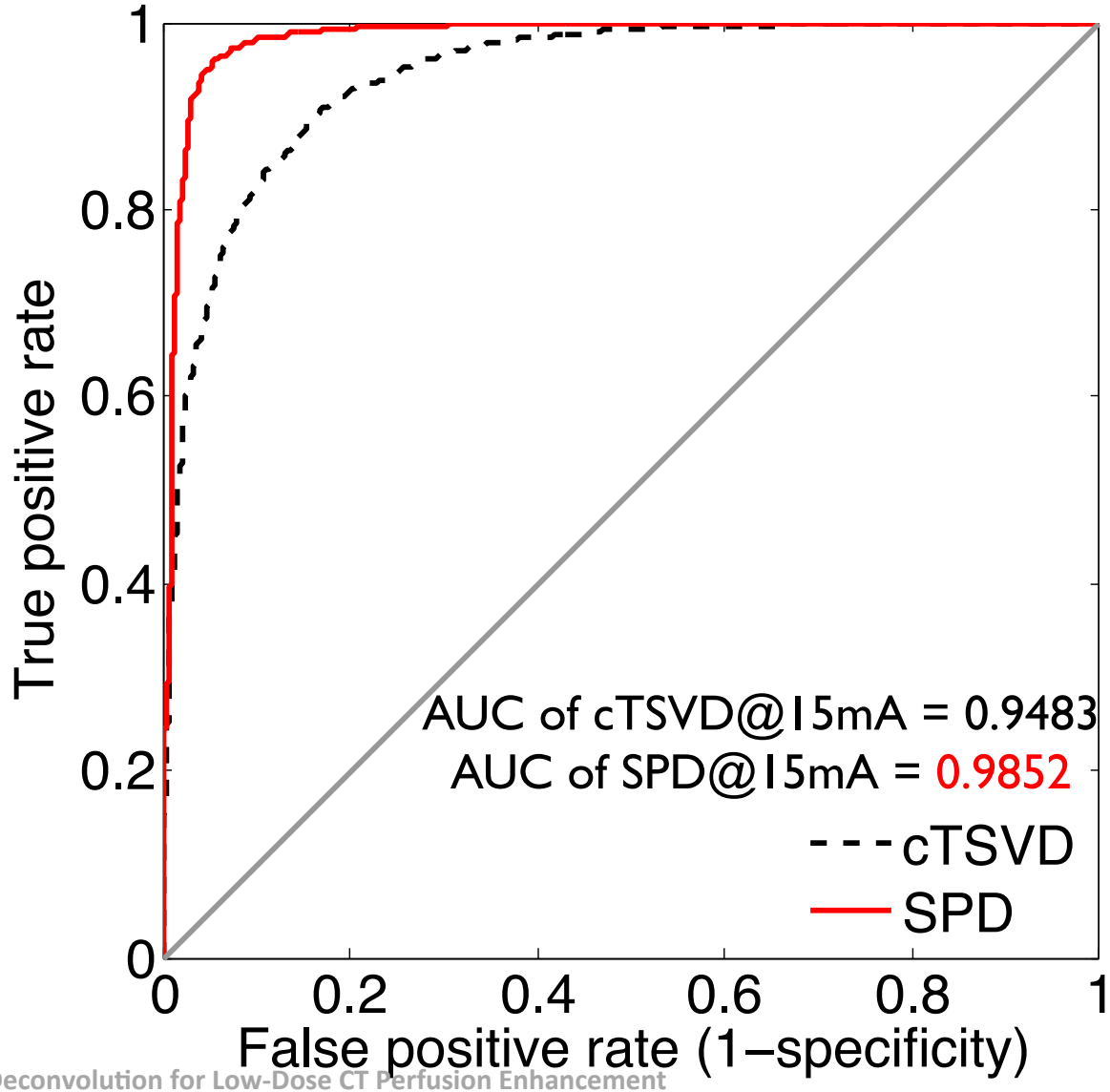

Conclusion



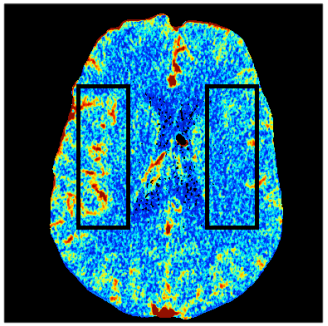

- Sparsity-based Deconvolution
  - Based on inter-patient similarity
  - Combine spatial and temporal models
  - Bridge the gap between high- and low-dose data

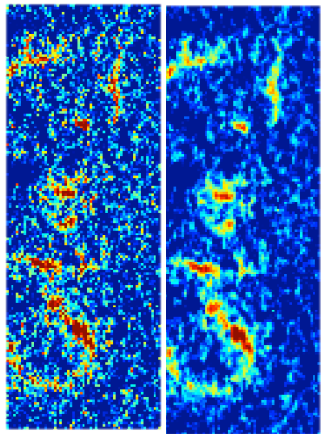

- Advantages
  - Learn compact dictionary of perfusion maps
  - Robust against: noise, varying contrast…
  - Enhanced visual quality and quantitative accuracy
  - Increase differentiation between normal and abnormal tissues

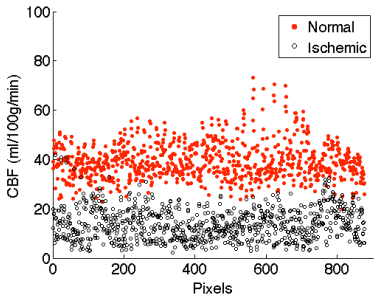

On-going Work: Discriminative Dictionaries

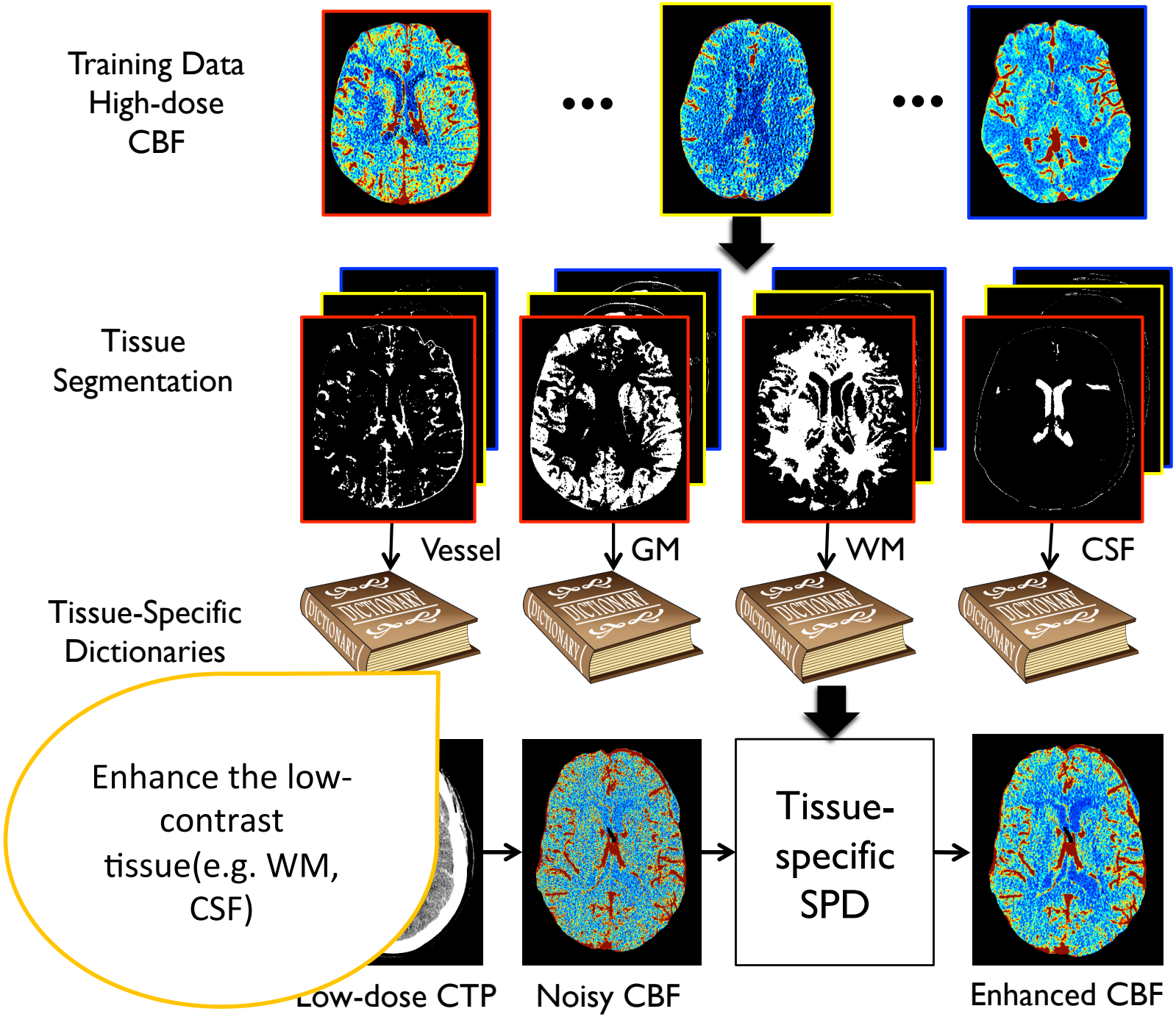

On-going Work: Blood-Brain Barrier Permeability Maps

- Hemorrhagic transformation (HT) is a serious and potentially fetal complication in patients with acute stroke.

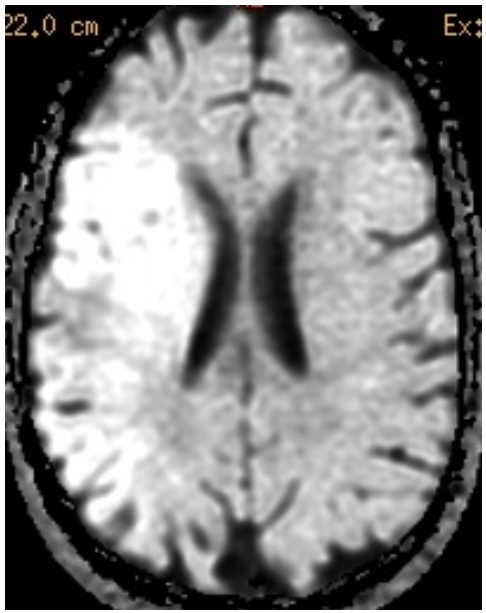

Diffusion weighted MRI shows the infarction in the right MCA territory (white).

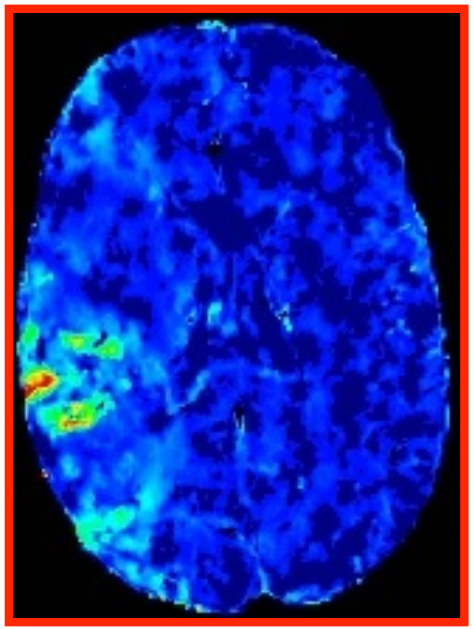

BBBP map shows increased BBBP in a small region of the right MCA territory (green/ red).

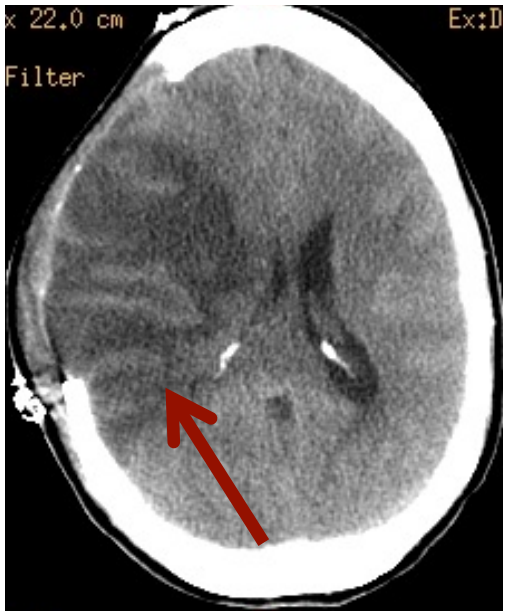

Follow-up CT without contrast shows that the area of infarction underwent hemorrhagic transformation (arrows). The BBBP map showed that this could happen.

Credit: Sanelli PC.

Acknowledgements

- Thank you for your attention!

- This work is supported by Grant Number 5K23NS058387-03S from the National Institute of Neurological Disorders and Stroke (NINDS), a component of the National Institutes of Health (NIH).